

Imaging finding in Different molecular cancer breast subtypes, A Cross Section study

Wael A. Maher EL Hik¹, Marwa Ibrahim M. Fahmy¹, Noha M. Gamal¹, Khaled A. Aly Shehata¹

¹ Radiology department, Ain Shams University, Cairo, Egypt

*Corresponding author: Wael A. Maher EL Hik, Email: Wael.maher@gmail.com

Abstract. Breast cancer is the major cause of death among women worldwide. For the sake of precision medicine, and since molecular subtyping of breast cancer is important to individualize its management, to understand prognosis of disease and avoid overtreatment, the gold standard for breast cancer management became the characterization of breast cancer molecular subtypes. Objectives: The present study aimed to detect the correlation between describe Mammogram and Ultrasound morphological features and in different molecular subtypes of breast cancer. Methods: A cross-sectional study conducted on all patients (227 in total) who were referred to the Radiology Department –at Ain-Shams University Hospital presented with breast lumps and /or bloody nipple discharge, patients with benign findings were excluded and all suspicious patients were biopsied and all biopsies received histopathology with immunohistochemistry until a sample size of 100 patients were achieved. Results: The mean age was 51.32±11.33 years, Luminal A (57%), Luminal B (17%), Human epidermal growth factor overexpression (13%), and Triple Negative Breast cancer (13%), with the youngest mean age being in Luminal A subtype (51.28±12.29 years) and the oldest mean age being in TNBC (58.46±13.26 years).. On Mammogram the majority of the masses were seen in the UOQ (70%) The most common mass shape was irregular in Luminal A (47.37%),. The most common margin was circumscribed. 92.86% of the tumors had high density, the highest mass density percentage was in Luminal A subtype, followed by Luminal B subtype with 88.24% high density the most common calcifications type was mixed, that HER+ subtype had the highest percentage of fine linear. In ultrasound, there was similar results concerning shape and margin, No tumors larger than 3 cm were reported for Luminal B or HER2-positive subtypes. No calcification in mass & intra ductal have been shown in Luminal A. Internal vascularity appeared in all patients with subtype Luminal B and HER+. Most of our study pathology came back to have Luminal A as the most dominating molecular subtype with 57% while the Luminal B was the second most common being 17% of the sample size. In contrast Mammography, the most common Mammography finding was mass with enhancement, most in Luminal A while TNBC having the highest percentage of parenchyma enhancement (53.85%). Calcification with enhancement was observed only in HER2-positive subtype, and calcification with no enhancement was observed only in Luminal B. Conclusion: Breast cancer has numerous subtypes that might help in better precision due to the feasibility of repeated measurements for whole tumors and our ability to follow up by all noninvasive studies.

Keywords: Breast neoplasms, Breast cancer, ultrasound features, Mammogram features, Molecular subtypes.

Introduction

Breast cancer presents with different morphologic and molecular features. The histopathological characteristics of tumors had been used to determine the management of breast cancer. (Sood R, et al, 2019). Ultrasonography and Mammography are two economical and accessible non-invasive radiological tests that are crucial for early identification, rapid treatment that increases the survival rate (Assi et al., 2013).

Combining Mammography and ultrasound screening decreased the death risk from breast cancer by 15% in women between the ages of 49 and 40 and by 22% over the age of 50. Yet breast density has a significant impact on Mammography sensitivity since Mammography

sensitivity decreases as breast density increases with age by 30% to 48% (Berg et al., 2010). The sensitivity of Mammography and Ultrasonography varies in various research conducted across the world. Yet early detection and treatment can help to lessen the Mortality (Alhamami et al., 2018).

In comparison to Mammography, Ultrasound was less expensive, radiation-free, portable, and more readily available. As a second-look technique for women with Mammographically occult lesions and differentiating between a cystic and a solid mass (Dixon, 2008).

It is proven that both exhibit comparable overall accuracy, elevated sensitivity and detection rates, and considerably reduced specificity (Yuan et al., 2020 & Wang et al., 2020). Breast Ultrasound is used to

supplement Mammography in certain clinical scenarios. Imaging palpable breast abnormalities has been shown to be extremely successful with breast ultrasound. It separates solid from cystic masses and shows the characteristics of solid masses that would indicate the mass as worrisome and necessitate biopsy (Sood R et al., 2019).

A Mammogram aids in locating breast lesions that are morphologically suspicious. Asymmetrical calcifications, masses. Other imaging views, such as point compression, magnification, and real lateral views, are necessary to identify local features and abnormalities if the lesion is suspected. , while in dense breast , the usage of contrast with conventional mammography gives a superadded value to detection accuracy , The American College of Radiology's Breast Imaging Reporting and Data System (BIRADS) harmonizes Mammography terms (Gilbert F & Pinker-Domenig K, 2019).

Objectives

The present study aimed to describe Mammogram and Ultrasound morphological features in different molecular subtypes of breast cancer.

Methods

Study design: A cross-sectional study conducted on patients who are referred to the Radiology Department –at Ain Shams University Hospital presented with breast lumps and /or bloody nipple discharge.

Study Setting: at Ain Shams University Hospital for 12 months starting March 2021 till April 2022, the Date was collected and analyzed after the whole sample was complete .

Participants: we included all Adult Female patients (above 18 years old) who complained of palpable breast lump or nipple discharge and excluded Patients with history of previous breast cancer (recurrence) and Patients Diagnosed with another primary tumor. Variables: our basic variables were Luminal A, luminal B, HER2+, TNBC, and all were categorized according to cancer type and radiological findings.

Data sources/ measurement:

All patients after history taking about Onset and duration of symptoms. The Presence of lumps and their distribution, Presence of bloody nipple discharge or focal pain. , Family history of breast cancer ,Contraceptive history , were verbally consented for being part of the study, and detailed explanation of the examination was given , standard digital mammogram by a skilled

technologist was done in both CC and MLO views ,normal studies and benign findings were excluded , suspicious masses that was found to be ill circumscribed masses , speculated masses , with ductal extension or accompanied with calcifications were reported by two well-trained specialists with a complementary ultrasound by using 7–14 MHz linear array transducer was done at the same setting ,once confirmed suspicious masses on ultrasound with speculated margins , hyper vascularity or posterior acoustic enhancement or shadowing were biopsied as a golden standard for such cases , at least 4 cores were acquired and were sent to pathology with immunohistochemistry in all patients with positive biopsy , after the results come back , Contrast enhanced mammogram was arranged using nonionic low-osmolar iodinated contrast material administered to the patient intravenously at a dose of 1.5 mL/kg at a rate of 3 mL/sec. Two minutes after contrast material administration, standard bilateral craniocaudal (CC) and mediolateral oblique (MLO) imaging is performed by using a dual-energy technique. All the results were collected, the reviewed findings were according to the American College of Radiology Breast Imaging Reporting and Data System (ACR BIRADS) lexicon, soft copies of the reports and some significant findings were archived.

Bias:

All data resulted from the studies were reported and presented in an excel sheet to assure honesty and to avoid Bias.

Study size:

100 cases met the eligibility criteria of our study. The sample size was decided by the faculty as a focus group.

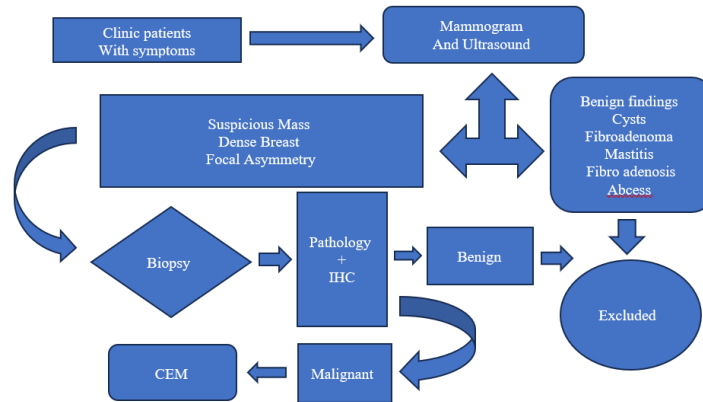
Statistical methods:

Using SPSS All four groups were subjected to two main statistical methods were used in the data analysis: descriptive statistics, which summarized data using indexes such as mean and standard deviation and the inferential statistics, which draw conclusions from data using statistical tests such as chi-square and t-test. Using immunohistochemistry, will be classified into 4 major molecular subtypes: Luminal A, Luminal B, Her2+, and TNBC. The findings will be categorized into 4 categories based on the molecular biology findings Under each category we will present the available radiological techniques findings common major radiological findings of each type of the detected breast cancer

Results

277 patients participated in our study, patients with benign findings like mastitis, fibro adenosis, breast cysts, abscess and fibroadenomas were excluded from this study on multiple stages, all 277 had their mammograms and

ultrasounds, only 188 were biopsied after exclusion of previously mentioned benign patients, only 106 came with back positive finding of cancer with one of the four subtypes indicated in the immunohistochemistry . 100 patients agreed to have Contrast enhanced Mammography while the rest refused contrast injection. (Flow-chart (1))



Flow chart (1): Summery of the study.

The mean age of patients were 51.32±11.33 years, Luminal A was 57% ,while Luminal B was 17%, HER2+ was 13% , and TNBC (13%)., with the youngest mean age being in Luminal A subtype (51.28±12.29 years) and

the oldest mean age being in TNBC (58.46±13.26 years). Age group between 41-50 years showed the highest range of Luminal A. The second highest range of Luminal A was shown in age group from 32-40 years old. (table 1)

Age Group	Diagnosis									
	Invasi on ductal carcin o-ma	LOBULA R CARCINO MA	MUCINO US CARCINO MA	METAPLA STIC CARCINO MA	PAPILLAR Y CARCONO MA	DCIS	Luminal A	Luminal B	HER+	TRIPLE NEGATI VE
32-40	15	5	1	0	0	2	14	5	3	1
41-50	18	3	1	2	2	2	17	4	4	3
51-60	12	3	1	1	1	2	12	4	3	1
61-70	14	3	1	0	0	0	10	1	1	6
71-77	8	0	0	2	0	1	4	3	2	2

Table 1. Age groups versus diagnosis and subtypes of cancer breast .Age group between 41-50 years showed the highest range of invasive ductal carcinoma andLuminal A.

The most common margin type for all subtypes combined was circumscribed. 92.86% of the tumors had high density, the highest mass density percentage was in Luminal A

subtype, Followed by Luminal B subtype with 88.24% high density, the most common calcifications type was mixed, with 8 out of 14 tumors having complex calcifications in mass.

Table 2. Mass margin findings among the subtypes of breast cancer

	Luminal A (n=57)	Luminal B (n=17)	HER+ (n=13)	Triple Negative (n=13)
Circumscribed	0	1(5.88%)	3(23.08%)	8(61.53%)
Obscured	0	0	9(69.23%)	0
Lobular	4(7.02%)	16(94.12%)	0	0
indistinct	0	0	0	4(30.77%)
Speculated	43(75.44%)	0	0	0

The above table that the highest percentage of Circumscribed has been noticed in Triple Negative subtype (61.53%) followed by HER+ (23.08%) then Luminal B (5.88%), while Luminal A subtype showed no Circumscribed.

No Obscured has been noticed in all subtypes except HER+ showed 69.23% of Obscured. Lobular showed the highest percentage (94.12%) in Luminal B subtype followed by 7.02% in Luminal A, while no Lobular mass

margin in Triple Negative and HER+. Speculated mass margin noticed in Luminal A subtype only with percentage of (75.44%).

On Mammogram the majority of the masses were seen in the UOQ (70%) while UIQ was (14%). The most common mass shape for all subtypes combined was irregular in Luminal A (47.37%), followed by oval (35.08%). The majority of the tumors were 0-3 cm in size.

Table 3. Mass shape findings among the subtypes of breast cancer

	Luminal A (n=57)	Luminal B (n=17)	HER+ (n=13)	Triple Negative (n=13)
Rounded	4 (7.02%)	0	2 (15.38%)	3 (23.08%)
Oval	20 (35.09%)	1 (5.88%)	1 (7.69%)	5 (38.46%)
Lobular	7 (12.28%)	0	0	4 (30.77%)
Irregular	27 (47.37%)	16 (94.11%)	9 (69.23%)	4 (30.77%)

The above table revealed that no rounded mass shape in the Luminal subtype, while the percentage in Triple Negative was 23.08% followed by HER+ with 15.38% then Luminal A was 7.02%. Taking in consideration that the number of cases are different in the 3 groups. The oval mass shape appeared in all subtypes but the highest percentage was in Luminal A (20%), and the least percentage appeared in Luminal B & HER+ subtypes.

The Lobular mass shape was absent in both subtypes of Luminal B & HER+, while was found in Luminal A & Triple negative subtypes. The irregular mass shape

appeared in all subtypes and the highest percentage was in Luminal A subtype followed by Luminal B, then HER+ and the lowest percentage was noticed in Triple negative subtype.

As regard calcifications, that HER+ subtype had the highest percentage of fine linear (84.62%), followed by Luminal A with percentage of 43.86%. The highest percentage of linear calcification (84.62%), the diffuse calcifications appeared in Luminal A only with a percentage of 40.35%.

Table 4. Calcifications Type findings among the subtypes of breast cancer

	Luminal A (n=57)	Luminal B (n=17)	HER+ (n=13)	Triple Negative (n=13)
Fine Pleomorphic	0	5(29.41%)	2(15.38%)	3(23.08%)
Fine Linear	25 (43.86%)	3(17.65%)	11(84.62%)	0

Amorphous	7(12.28%)	0	0	0
Coarse heterogenous	0	0	0	0

According to calcifications, the above table revealed that HER+ subtype had the highest percentage of fine linear (84.62%), followed by Luminal A with percentage of 43.86%. In ultrasound, there was similar results concerning shape and margin, for Luminal A subtype fell in the range of zero to 3 cm (71.93%), followed by 22.81% of tumors in the range of 3 to 5 cm, and 7.02% of tumors bigger than 5 cm. On the other hand, Luminal B subtype had 100% of its tumors in the range of zero to 3 cm, while

HER2-positive subtype had 76.92% of its tumors in the same range.

No tumors larger than 3 cm were reported for Luminal B or HER2-positive subtypes. TNBC had no tumors in the range of zero to 3 cm. No calcification in mass & intra-ductal have been shown in Luminal A. Internal vascularity appeared in all patients with subtype Luminal B and HER+.

Table 5. Mass shape findings among the subtypes of breast cancer

	Luminal A (n=57)	Luminal B (n=17)	HER+ (n=13)	Triple Negative (n=13)
Rounded	0	0	2(15.38%)	3(23.08%)
Oval	16(28.07%)	1(5.88%)	0	4(30.77%)
Micro lobulated	8(14.04%)	0	0	1(7.69%)
Irregular	39(68.42%)	16(94.12%)	10(76.92%)	5(38.46%)

From the previous table we noticed that rounded mass shape appeared in both HER+ and Triple negative subtypes with higher percentage in triple negative. Oval mass shape was higher in triple negative followed by Luminal A,

Irregular mass shape appeared in the 4 subtypes with highest percentage in Luminal B (76.92%), followed by Luminal B (94.12%) then Luminal A (67.42%).

Table 6. Mass orientation findings among the studied patients

	Luminal A (n=57)	Luminal B (n=17)	HER+ (n=13)	Triple Negative (n=13)
Parallel	33(57.89%)	1(5.88%)	2(15.38%)	3(23.08%)
Anti-parallel	24(42.11%)	16(94.12%)	10(76.92%)	10(76.92%)

The above table demonstrated that the highest parallel mass orientation appeared in Luminal A, the highest anti parallel mass orientation shown Luminal B. - HER+ and

Triple negative subtypes showed the same percentage of Mass orientation

Table 7. Posterior features findings among the studied patients

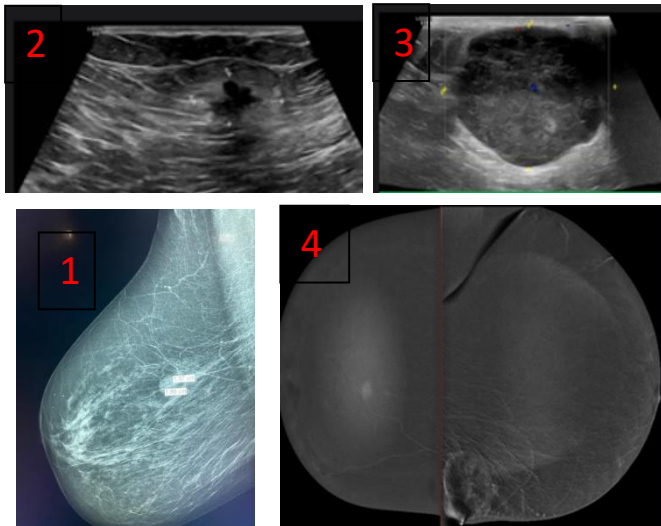
	Luminal A (n=57)	Luminal B (n=17)	HER+ (n=13)	Triple Negative (n=13)
Enhancement	0	2(11.76%)	4(30.77%)	3(23.08%)
Shadowing	53(92.98%)	8(47.06%)	0	1(7.69%)
combined	0	6(35.29%)	7(53.85%)	1(7.69%)
No Features	17(29.82%)	1(5.88%)	0	8(61.54%)

In contrast Mammography, the most common Mammography finding across all subtypes was mass with enhancement, Ranging from 53.84% for Her2-positive to 84.21% for luminal A with rim enhancement (12.79%) and TNBC having the highest percentage

of parenchyma enhancement (53.85%). Calcification with enhancement was observed only in HER2-positive subtype, and calcification with no enhancement was observed only in Luminal B.

Table 8.CEM findings among the studied patients

	Luminal A (n=57)	Luminal B (n=17)	HER+ (n=13)	Triple Negative (n=13)
Mass + Enhancement	48(84.21%)	10(58.82%)	7(53.84%)	7(53.85%)
Mass + Rim Enhancement	9(12.79%)	2(11.76%)	1(7.69%)	2(15.38%)
Calcification + Enhancement	0	0	1(7.69%)	0
Calcification + No Enhancement	0	5(29.41%)	0	0
Distorsion + Enhancement	0	0	1(7.69%)	4
Distorsion + No Enhancement	0	0	0	0
BPE (Breast parancyma enhancment)	0	0	0	7(53.85%)



A 37-year-old female with bleeding nipple

1- Mammogram had high density oval mass lesion in the right breast with well circumscribed margins and no calcifications

2- Right breast ultrasound showed small hypoechoic ill circumscribed speculated lesion with internal break down and posterior shadowing

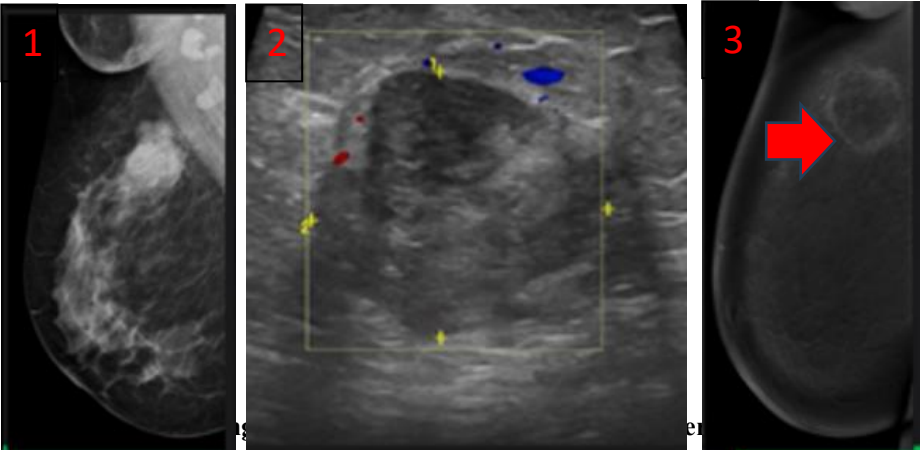
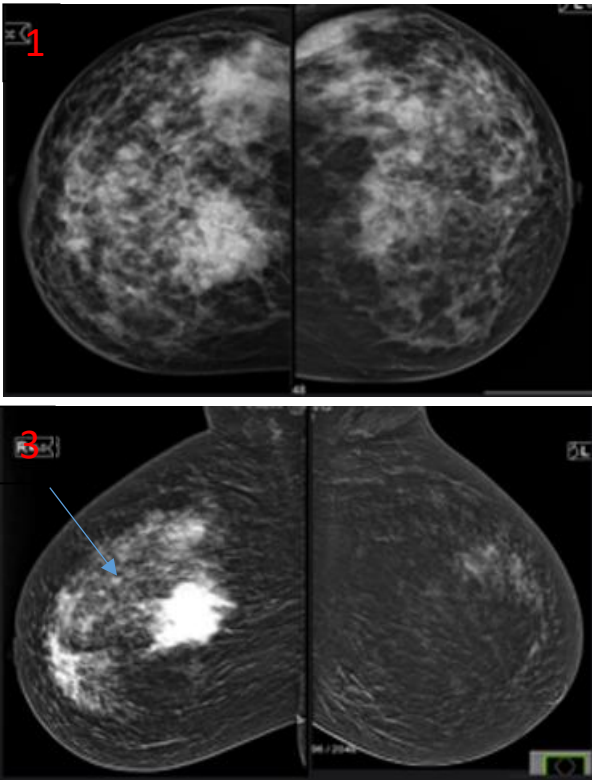
3- Left breast ultrasound showed a well circumscribed 2.5 cm hypoechoic lesion with posterior enhancement.

4- CEM the right lesion showed enhancement while the left breast showed rim enhancement

biopsy proven IDC on both lesions , immunohistochemistry was (Luminal A)

A 42 year old female with painful lump in the right breast – 1- in the mammogram it was a dense breast of ACR C with suspicious high density mass lesion , the ultrasound revealed a speculated mass lesion , 2- the contrast enhanced mammography showed mass enhancement seen – 3- non mass enhancement seen in delayed images (blue arrow)

Pathology of the case was intra ductal carcinoma and the Immunohistochemistry was HER2+



1- A 32 year old female with a hard lump has dense well circumscribed mass in the right Side UOQ in mammogram .

2- Ultrasound revealed 2.8x 3.2 cm rounded hypoechoic mass lesion with peripheral and internal vascularity

3- The CEM showed Rim enhancement (red arrow)

The Pathology was Lobular carcinoma

Immunohistochemistry was triple negative breast cancer

Age group between 41-50 years showed the highest range of Luminal A, Celebi et al (2015) reported that most of LA patients were above 50 years. While LB patients were less than 50 years of age. This slightly agreed with Rashmi et al. (2018) stated that patients with a mean age of 52 ± 11 years (range, 24–85 years); 41 (21%) were LA; 45 (23%) were LB; 24 (13%) were LB.

In our study, the most common mass shape was irregular (47.37%), followed by oval (35.08%) , with Luminal B subtype having the highest percentage of lobular mass shape (7.69%) and Luminal A subtype having the highest percentage of rounded mass shape (7.02%). Metwally et al. (2023) reported that, irregular-shaped lesions were significantly observed in LA subtype (88% of the cases) with a P value < 0.001 . In addition, 76% of LB cases and 73% of HER2 cases were associated with irregular shape (P < 0.001). In our study the majority of the tumor's sizes in both Mammogram and ultrasound, were 0-3 cm in size, with Luminal A subtype having (71.93%) of its tumors falling in this category. The HER+ and Luminal B subtypes had a higher percentage of tumors in the 3-5 cm size range (92.31% and 92.31%, respectively) .Metwally et al. (2023) reported that, tumors larger than 2 cm were associated with HER2+ status. Smaller lesions were significantly seen in hormone receptor ER and /or PR positive breast masses. TNBC lesions less than 2 cm were observed in one out of four patients, while the remaining three lesions were more than or equal 2 cm

In our study, Tumors with micro-calcifications on mammogram were strongly associated with HER2+. Cen et al. (2017) has shown good correlation between the Mammography detected suspicious micro calcifications and HER2+. Seo et al. (2006) and Zhang et al. (2015) found that calcifications were more frequent in HER2+ tumors than the other subtypes Patel et al. (2017) found that HER2+. tumors were more likely to have heterogeneous and pleomorphic micro-calcifications.

Metwally et al. (2023) reported that, calcifications was found to be clearly encountered in HER2+ (67%). Kojima and Tsunoda (2011) showed that the expression of HER2+ was strongly correlated with the presence of calcification. Also Whitman and Albarracin (2018) noticed that the presence of calcification was significantly associated with HER2+ status.

LA was the next most common molecular subtype with the highest percentage of linear calcification (84.62%), while diffuse calcifications was only (40.35%) , fine calcifications appeared in Luminal A subtype only, while regional calcifications was with Luminal B subtype. Cen et al. (2017) demonstrated that amorphous and heterogeneous coarse calcifications were associated with a

higher incidence of LA subtype while TNC showed less frequent micro-calcifications, this was confirmed by (Ko et al. 2010) who suggested that TN cancers have a more rapid pattern of carcinogenesis that leads directly to invasive cancer, with no major in situ component or precancerous stage It was obvious in ultrasound that Hypo-echoic Echo pattern we seen in all patients with Luminal A and about half the patients with TNBC, on analyzing the posterior acoustic pattern, luminal A subtype showed the highest shadowing posterior features percentage. Her2-enriched tumors frequently demonstrated either posterior enhancement or mixed (enhancement and shadowing) feature possibly due to presence of micro calcification. Irshad et al. (2013) also found tumors with posterior acoustic shadowing to have greater than nine times higher association with hormone receptor positivity., Celebi et al. (2015) found that tumors with posterior shadowing were found to have 10.58 times higher association with LA and LB subtypes Metwally et al. (2023) reported that, posterior shadowing was significantly associated with luminal tumors while posterior enhancement was found to be more observed with TNBC lesions (53%). Mixed enhancement and shadowing were associated with HER2 lesions which was observed in 53.3% of our HER2 cases.

Ko et al. (2015) showed that HER2 lesions were more associated with posterior enhancement. Hyper-echoic lesions were not found at all in all the examined masses. Hypo-echogenicity was significantly associated with TNBC (Kin et al., 2020). Tumors with well-circumscribed margins and posterior enhancement were strongly suggestive of TNBC type of breast cancer, which is the most aggressive type of breast cancer with rapid growth and necrosis (Anupama et al., 2017). And this was almost the same in our study.

In our study, internal vascularity appeared in all patients with subtype Luminal B and HER+. Rashmi et al. (2018) reported that, in contrast to LA, LB subtype was found to have higher degree of vascularity. Kojima and Tsunoda (2011), who reported 90% vascularity, which is somewhat higher than the rate found in our study (38% for TN cancers and 36.7% for HR-positive/HER-2-negative cancers) Anupama et al. (2017) found that triple-negative cancers were hyper vascular compared with non-triple-negative cancers. But our study revealed that this molecular type was less vascular than LB and HER2-enriched tumor, possibly due to more necrosis.

In CEM findings, the most common finding in all subtypes was mass with enhancement, ranging from 53.84% for HER2-positive to 84.21% for Luminal A. With Luminal A having the highest percentage of mass with rim enhancement (12.79%) and TNBC having the highest

percentage of breast parenchyma enhancement (53.85%). Calcification with enhancement was observed only in HER2-positive subtype, and calcification with no enhancement was observed only in Luminal B.

Distortion with enhancement was observed only in HER2-positive and TNBC, and distortion with no enhancement was not observed in any of the subtypes. Zhang et al. (2018) found that the different molecular subtypes (luminal A, luminal B, HER2 enriched, and basal-like) could be distinguished based on their CEM features Krawczyk et al. (2019) found that luminal A and luminal B subtypes had significantly different CEM features compared to HER2-enriched and basal-like subtypes. One study found that the enhancement intensity in CEM images of ER- or PR-positive lesions were weaker than that in CEM images of negative lesions, while HER2-positive lesions showed stronger enhancement than HER2-negative lesions (Liu et al., 2020). Metwally et al. (2023) reported that, parenchymal distortion was more observed in LA and HER2 subtypes. Kojima and Tsunoda (2011) showed that LB subtype was the least associated with architectural distortion.

Conclusion:

Molecular subtypes of breast cancer have some specific radiological criteria for each subtype, Luminal A and B have well circumscribed margins on mammogram and posterior shadowing in Ultrasound, HER2+ likely to have micro calcifications on Mammogram while TNBC lack suspicious features in mammogram. Contrast Mammogram is helpful in detection of occult masses in dense breast. Multiple similar further studies with larger samples are needed to confirm our results

References

- Alhamami Q, Almetlag M & Hussain M et al. Correlation of Ultrasound & Mammography to Histopathology Results in Breast Cancer. A One Year Study at King Khalid Hospital, Najran, Saudi Arabia. *The Egyptian Journal of Hospital Medicine*, 2018; 71(2): 2603-2609.
- Anupama T, Prachi S, Smita M, Neelam W, Natasha G, Navneet K, et al. Role of Sonography in predicting the hormone receptor status of breast cancer: A prospective study. *J Diagn Med Sonogr*. 2017;1–12.
- Assi HA, Khoury KE, Dbouk H, Khalil LE, Mouhieddine TH, El Saghir NS. Epidemiology and prognosis of breast cancer in young women. *J Thorac Dis*. 2013; 5 Suppl 1(Suppl 1): S2-S8. Doi: 10.3978/j.issn.2072-1439.2013.05.24
- Berg WA, Sechtin AG, Marques H, Zhang Z. Cystic breast masses and the ACRIN 6666 experience. *Radiol Clin North Am* 2010; 48(5):931–987.
- Boisserie-Lacroix M, Mac Grogan G, Debled M, Ferron S, Asad-Syed M, Brouste V, et al. Radiological features of triple negative breast cancers (about 73 cases) *Diagn Interv Imaging*. 2012; 93:196–203.
- Boisserie-Lacroix M, Macgrogan G, Debled M, Ferron S, Asad-Syed M, McKelvie-Sebileau P, Mathoulin-Pélissier S, Brouste V, Hurtevent-Labrot G. Triple-negative breast cancers: associations between imaging and pathological findings for triple-negative tumors compared with hormone receptor-positive/human epidermal growth factor receptor-2-negative breast cancers. *Oncologist*. 2013; 18(7):802-11.
- Celebi F, Pilanc K, Ordu C, et al. The role of ultrasonographic findings to predict molecular subtype, histologic grade, and hormone receptor status of breast cancer. *Diagnostic and Interventional Radiology*. 2015; 21:448-453 Cen D, Xu L, Li N, Chen Z, Wang L, Zhou S, et al. BI-RADS 3-5 microcalcifications can preoperatively predict breast cancer HER2 and Luminal a molecular subtype. *Oncotarget*. 2017; 8:13855–62.
- Dixon, A.M. *Breast Ultrasound: How, Why and When*; Churchill Livingstone: London, UK, 2008; ISBN 978-0-443-10076-5.
- Dogan BE, Gonzalez-Angulo AM, Gilcrease M, et al. Multimodality imaging of triple receptor- negative tumors with mammography, ultrasound, and MRI. *AJR Am J Roentgenol*. 2010; 194:1160–1166.
- Evans AJ, Rakha EA, Green AR, Ball G. Ellis I 0: The mammographic correlations of a new immunohistochemical classification of invasive cancer. *CLI*. 2018; 63:1228-1223
- Fletcher CD. *Diagnostic Histopathology of Tumors*. Elsevier; 2017 Gilbert FJ, Pinker-Domenig K. *Diagnosis and Staging of Breast Cancer: When and How to Use Mammography, Tomosynthesis, Ultrasound, Contrast-Enhanced Mammography, and Magnetic Resonance Imaging*. In: Hodler J, Kubik-Huch RA, von Schulthess GK, eds. *Diseases of the Chest, Breast, Heart and Vessels 2019-2022: Diagnostic and Interventional Imaging*. Cham (CH): Springer; February 20, 2019.155-166.
- Irshad A, Leddy R, Pisano E, Nathaniel Baker, Madelene Lewis, Susan A, et al. Assessing the role of ultrasound in predicting the biological behavior of breast cancer. *AJR Am J Roentgenol*. 2013; 200:284–90.
- Itoh A, Ueno E, Tohno E, Kamma H, Takahashi H, Shiina T, et al. Breast disease: clinical application of US elastography for diagnosis. *Radiology*. 2006; 239:341–50.
- Kin J, Yu D, Youngmee K, et al. Genomic characteristics of breast Cancer nominate molecular subtypes that predict chemotherapy response. *Molecular Cancer Research*. 2020; 19(3):1541-1558 Ko ES, Lee BH, Kim HA, et al. Triple-negative breast cancer: Correlation between imaging and pathological findings. *Eur Radiol*. 2010; 20:1111–1117.

15. Ko ES, Lee BH, Kim HA, Noh WC, Kim MS, Lee SA. Triple-negative breast cancer: Correlation between imaging and pathological findings. *European Radiology*. 2015; 20(5):1111-1117
16. Kojima Y, Tsunoda H. Mammography and ultrasound features of tripfe-negative breast-cancer. *Breast Cancer*. 2011; 18(3):146-151
17. Lam SW, Jimenez CR, Boven E. Breast cancer classification by proteomic technologies: Current state of knowledge. *Cancer Treat Rev*. 2014; 40:129–38.
18. Larsen MJ, Kruse TA, Tan QH, et al. Classifications within molecular subtypes enables identification of BRCA1/BRCA2 mutation carriers by RNA tumor profiling. *PLoS*. 2013; 8: e64268
19. Metwally ES, Alghazal RM, Ali AH. Correlation between Ultrasound Findings and Molecular Subtypes of Breast Cancer. *InBreast Cancer Updates 2023 Jan 18*. IntechOpen.
20. Patel TA, Puppala M, Ogunti RO, Ensor JE, He T, Shewale JB, et al. Correlating mammographic and pathologic findings in clinical decision support using natural language processing and data mining methods. *Cancer*. 2017; 123:114–21.
21. Rashmi S, Kamala S, Murthy SS, Kotha S, Rao YS, Chaudhary KV. Predicting the molecular subtype of breast cancer based on mammography and ultrasound findings. *Indian J Radiol Imaging*. 2018 Jul-Sep; 28(3):354-361.
22. Seo BK, Pisano ED, Kuzimac CM, Koomen M, Pavic D, Lee Y, et al. Correlation of HER-2/ne overexpression with mammography and age distribution in primary breast carcinomas. *AcadRadiol*. 2006; 13:1211–8.
23. Sood R, Rositch AF, Shakoor D, et al. Ultrasound for Breast Cancer Detection Globally: A Systematic Review and Meta-Analysis. *J Glob Oncol*. 2019; 5:1-17. doi:10.1200/JGO.19.00127
24. Wang Y, Ikeda DM, Narasimhan B, Longacre TA, Bleicher RJ, Pal S, et al. Estrogen receptor- negative invasive breast cancer: imaging features of tumors with and without human epidermal growth factor receptor type 2 overexpression. *Radiology*. 2008; 246:367–75.
25. Wang, J.; Zheng, S.; Ding, L.; Liang, X.; Wang, Y.; Greuter, M.J.W.; de Bock, G.H.; Lu, W. Is Ultrasound an Accurate Alternative for Mammography in Breast Cancer Screening in an Asian Population? A Meta-Analysis. *Diagnostics* 2020, 10, 985.
26. Whitman GJ, Albarracin CT. Triple negative breast cancer: What the radiologist needs to know. *Seminars in Roentgenology*. 2018; 46(1):26-39
27. Willett AM, Michell MJ, Lee MJ Best Practice Diagnostic Guidelines for Patients Presenting with Breast Symptoms, 2010.
28. Yang WT, Dryden M, Broglio K, Gilcrease M, Dawood S, Dempsey PJ, et al. Mammographic features of triple receptor-negative primary breast cancers in young premenopausal women. *Breast Cancer Res Treat*. 2008; 111:405–10.
29. Yuan, W.-H.; Hsu, H.-C.; Chen, Y.-Y.; Wu, C.-H. Supplemental Breast Cancer-Screening Ultrasonography in Women with Dense Breasts: A Systematic Review and Meta-Analysis. *Br. J. Cancer* 2020, 123, 673–688.
30. Zhang L, Li J, Xiao Y, Cui H, Du G, Wang Y, et al. Identifying ultrasound and clinical features of breast cancer molecular subtypes by ensemble decision. *Sci Rep*. 2015; 5:11085.